

M1830: Bathing Answer Grid

Response	Environment	Assistance
0	In tub/shower	None
1	In tub/shower	Devices
2	In tub/shower	Intermittent Assistance
3	In tub/shower	Presence of Another Throughout
4	Sink/chair/commode/BSC	No human assistance
5	Bed/sink/chair/commode/BSC	Presence of Another Throughout
6	Unspecified	Totally Dependent

Supportive Toolbox Information: Example

Instrument	Score Interpretation	Source Documents	Psychometric Properties	Clinical Tips
Timed Up & Go	<p><10 seconds = normal</p> <p>>14 seconds = ↑ fall risk</p> <p>≤ 20 seconds = mostly independent</p> <p>≤ 30 seconds = moderately impaired</p> <p>>30 seconds = severely impaired + ADL dysfunction</p>	<p>1. Podsiadlo D, Richardson S. The Timed Up & Go: A test of basic functional mobility for frail elderly persons. <i>J AM Geriatr Soc</i> 1991; 39: 142-8.</p> <p>2. Steffen TM, Hacker TA, Mollinger L. Age-and gender-related test performance in community dwelling elderly people: six-minute walk test, Berg balance scale, timed up & go test, and gait speed. <i>Phys Ther</i> 2002; 82</p> <p>3. shumway-Cook A, Brauer S, Woollacott M. Predicting the probability for falls in community dwelling older adults using the timed up and go test. <i>Phys ther</i> 2000; 80:896-903.</p> <p>4. Bohannon RW. 2003. Reference values for the Timed "Up and Go" test: a descriptive meta-analysis. <i>Journal of Geriatric Physical Therapy</i>. 29 (2): 64-68</p>	<p>Reliability (ICC) = .992</p> <p>Sensitivity for predicting falls = 0.80</p> <p>Specificity for predicting falls = 0.934</p> <p>Additional info: *scores <20secs – independent in transfers *scores >30secs – dependent *mod-high correlation with Berg, gait speed, Barthel ADL scale</p>	<p><u>Test instructions:</u> complete 2 trials and average together for score</p> <p>*Document score as xx.x secs</p> <p><u>Patient Related Activities:</u></p> <ol style="list-style-type: none"> 1. Address presence/use of assistive device with scores > 14 seconds 2. Consider referral to OT for scores > 30 seconds 3. Educate patient/CG on transfer safety with scores > 20 seconds <p><u>OASIS-C Process Measures:</u> Appropriate standardized test for completion of M1910 for ambulatory patients Note: This is a measure of mobility impairment</p>

Dyspnea Scale

Grade

- 0 "I only get breathless with strenuous exercise"
- 1 "I get short of breath when hurrying on the level or walking up a slight hill"
- 2 "I walk slower than people of the same age on the level because of breathlessness or have to stop for breath when walking at my own pace on the level ground"
- 3 "I stop for breath after walking about 100 yards or after a few minutes on the level ground"
- 4 "I am too breathless to leave the house" or "I am breathless when dressing"

NB: This is the modified MRC scale that uses the same descriptors as the original MRC scale in which the descriptors are numbered 1-5. The modified MRC scale (0-4) is used for calculation of BODE index.

MMRC Dyspnea Scale

Grade	Description of Breathlessness
0	I only get breathless with strenuous exercise.
1	I only get short of breath when hurrying on level ground walking up a slight hill.
2	On level ground, I walk slower than people of the same age because of breathlessness, or have to stop for breath when walking at my own pace.
3	I stop for breath after walking about 100 yards or after a few minutes on level ground.
4	I am too breathless to leave the house or I am breathless when dressing.

WOUND OSTOMY CONTINENCE NURSES SOCIETY
GUIDANCE ON OASIS-C INTEGUMENTARY ITEMS

Wound Ostomy Continence Nurses Society
Guidance on OASIS-C Integumentary Items

WOCN OASIS Taskforce

Members:

Ben Peirce (Chairperson), RN, BA, CWOCN, COS-C
Dianne Mackey, BSN, RN, PHN, CWOCN
Laurie McNichol, MSN, RN, GNP, CWOCN

WOUND OSTOMY CONTINENCE NURSES SOCIETY GUIDANCE ON OASIS-C INTEGUMENTARY ITEMS

OVERVIEW AND BACKGROUND

OASIS-C is a modification to the Outcome and Assessment Information Set (OASIS) that Home Health Agencies must collect in order to participate in the Medicare program. This is the first major update of the OASIS since it was implemented in 2000.

It includes removing items not used for payment or quality, adding items to address clinical domains not covered, modified wording for selected items and adding process items that support measurement of evidence based practices. The system for wound classification uses terms that lack universal definition and clinicians have verbalized concerns that they may be interpreting these terms incorrectly. The WOCN Society has therefore developed the following guidelines for the classification of wounds. These items were developed by consensus among the WOCN Society panel of content experts.


(M1300) Pressure Ulcer Assessment: Was this patient assessed for risk of developing pressure ulcers?

(M1302) Does this patient have a Risk of Developing Pressure Ulcers?

(M1306) Does this patient have at least one Unhealed Pressure Ulcer at Stage II or Higher or designated as "unstageable"?


Definitions:

- **Unhealed:** The absence of the skin's original integrity.
- **Non-epithelialized:** The absence of regenerated epidermis across a wound surface.
- **Pressure Ulcer:** A *pressure ulcer* is localized injury to the skin and/or underlying tissue, usually over a bony prominence, as a result of pressure or pressure in combination with shear and/or friction. A number of contributing or confounding factors are also associated with pressure ulcers; the significance of these factors is yet to be elucidated.
- **Pressure Ulcer Stages (NPUAP 2007):**



Stage I. A Stage I pressure ulcer presents as intact skin with non-blanchable redness of a localized area, usually over a bony prominence. Darkly pigmented skin may not have visible blanching; its color may differ from the surrounding area.

Further description. The area may be painful, firm, soft, and warmer or cooler as compared to adjacent tissue. Stage I ulcers may be difficult to detect in individuals with dark skin tones and may indicate "at risk" persons (a heralding sign of risk).




Stage II. A Stage II pressure ulcer is characterized by partial-thickness loss of dermis presenting as a shallow open ulcer with a red-pink wound bed without slough. It also may present as an intact or open/ruptured serum-filled blister.

Further description. A Stage II ulcer also may present as a shiny or dry shallow ulcer without slough or bruising. This stage*


WOUND OSTOMY CONTINENCE NURSES SOCIETY GUIDANCE ON OASIS-C INTEGUMENTARY ITEMS

should not be used to describe skin tears, tape burns, perineal dermatitis, maceration, or excoriation. * Bruising indicates suspected deep tissue injury.



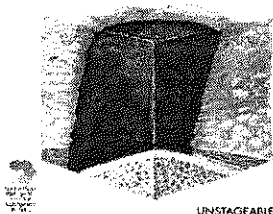
Stage III. A Stage III pressure ulcer is characterized by full-thickness tissue loss. Subcutaneous fat may be visible but bone, tendon, or muscle is not exposed. Slough may be present but does not obscure the depth of tissue loss. Stage III ulcers may include undermining and tunneling.

Further description. The depth of a Stage III pressure ulcer varies by anatomical location. The bridge of the nose, ear, occiput, and malleolus do not have subcutaneous tissue; Stage III ulcers in these locations can be shallow. In contrast, areas of significant adiposity can develop extremely deep Stage III pressure ulcers. Bone/tendon is not visible or directly palpable.




Stage IV. A Stage IV pressure ulcer presents with full-thickness tissue loss with exposed bone, tendon, or muscle. Slough or eschar may be present on some parts of the wound bed. These ulcers often include undermining and tunneling.

Further description. The depth of a Stage IV pressure ulcer varies by anatomical location. The bridge of the nose, ear, occiput, and malleolus do not have subcutaneous tissue; Stage IV ulcers in these locations can be shallow. Stage IV ulcers can extend into muscle and/or supporting structures (eg, fascia, tendon, or joint capsule); osteomyelitis is possible. Exposed bone/tendon is visible or directly palpable.



Unstageable. Full-thickness tissue loss in which the base of the ulcer is covered by slough (yellow, tan, gray, green or brown) and/or eschar (tan, brown or black) in the wound bed may render a wound unstageable.

Further description. Until enough slough and/or eschar is removed to expose the base of the wound, the true depth (and therefore, the stage) cannot be determined. Stable (dry, adherent, intact without erythema or fluctuance) eschar on the heels serves as "the body's natural (biological) cover" and should not be removed.



Suspected Deep Tissue Injury. Deep tissue injury may be characterized by a purple or maroon localized area of discolored intact skin or a blood-filled blister due to damage of underlying soft tissue from pressure and/or shear. Presentation may be preceded by tissue that is painful, firm, mushy, boggy, and warmer or cooler as compared to adjacent tissue.

Further description. Deep tissue injury may be difficult to detect in individuals with dark skin tones. Evolution may include a thin blister over a dark wound

WOUND OSTOMY CONTINENCE NURSES SOCIETY GUIDANCE ON OASIS-C INTEGUMENTARY ITEMS

bed. The wound may further evolve and become covered by thin eschar. Evolution may be rapid, exposing additional layers of tissue even with optimal treatment.

(M1307) The Oldest Non-epithelialized Stage II Pressure Ulcer that is present at discharge

(M1308) Current Number of Unhealed (non-epithelialized) Pressure Ulcers at Each Stage

(M1310) Pressure Ulcer Length: Longest length "head-to-toe"

(M1312) Pressure Ulcer Width: Width of the same pressure ulcer; greatest width perpendicular to the length

(M1314) Pressure Ulcer Depth: Depth of the same pressure ulcer; from visible surface to the deepest area

(M1320) Status of Most Problematic (Observable) Pressure Ulcer

- 0 - Newly epithelialized**
- 1 - Fully granulating**
- 2 - Early/partial granulation**
- 3 - Not healing**
- NA - No observable pressure ulcer**

Definitions:

- **Newly epithelialized**
 - wound bed completely covered with new epithelium
 - no exudate
 - no avascular tissue (eschar and/or slough)
 - no signs or symptoms of infection
- **Fully granulating**
 - wound bed filled with granulation tissue to the level of the surrounding skin
 - no dead space
 - no avascular tissue (eschar and/or slough)
 - no signs or symptoms of infection
 - wound edges are open
- **Early/partial granulation**
 - ≥25% of the wound bed is covered with granulation tissue
 - < 25% of the wound bed is covered with avascular tissue (eschar and/or slough)
 - no signs or symptoms of infection
 - wound edges open
- **3 - Not healing**
 - wound with ≥25% avascular tissue (eschar and/or slough) OR
 - signs/symptoms of infection OR
 - clean but non-granulating wound bed OR
 - closed/hyperkeratotic wound edges OR
 - persistent failure to improve despite appropriate comprehensive wound management

WOUND OSTOMY CONTINENCE NURSES SOCIETY GUIDANCE ON OASIS-C INTEGUMENTARY ITEMS

(M1322) Current Number of Stage I Pressure Ulcers

(M1324) Stage of Most Problematic Unhealed (Observable) Pressure Ulcer

(M1330) Does this patient have a Stasis Ulcer?

(M1332) Current Number of (Observable) Stasis Ulcer(s)

(M1334) Status of Most Problematic (Observable) Stasis Ulcer

- 0 - Newly epithelialized**
- 1 - Fully granulating**
- 2 - Early/partial granulation**
- 3 - Not healing**
- NA - No observable stasis ulcer**

Definitions:

- **Newly epithelialized**
 - wound bed completely covered with new epithelium
 - no exudate
 - no avascular tissue (eschar and/or slough)
 - no signs or symptoms of infection
- **Fully granulating**
 - wound bed filled with granulation tissue to the level of the surrounding skin
 - no dead space
 - no avascular tissue (eschar and/or slough)
 - no signs or symptoms of infection
 - wound edges are open
- **Early/partial granulation**
 - $\geq 25\%$ of the wound bed is covered with granulation tissue
 - $< 25\%$ of the wound bed is covered with avascular tissue (eschar and/or slough)
 - no signs or symptoms of infection
 - wound edges open
- **3 - Not healing**
 - wound with $\geq 25\%$ avascular tissue (eschar and/or slough) OR
 - signs/symptoms of infection OR
 - clean but non-granulating wound bed OR
 - closed/hyperkeratotic wound edges OR
 - persistent failure to improve despite appropriate comprehensive wound management

(M1340) Does this patient have a Surgical Wound?

WOUND OSTOMY CONTINENCE NURSES SOCIETY GUIDANCE ON OASIS-C INTEGUMENTARY ITEMS

(M1342) Status of Most Problematic (Observable) Surgical Wound:

- 0 - **Newly epithelialized**
- 1 - **Fully granulating**
- 2 - **Early/partial granulation**
- 3 - **Not healing**
- NA - **No observable surgical wound**

Definitions:

- o **Newly epithelialized**
 - o wound bed completely covered with new epithelium
 - o no exudate
 - o no avascular tissue (eschar and/or slough)
 - o no signs or symptoms of infection
- o **Fully granulating**
 - o wound bed filled with granulation tissue to the level of the surrounding skin
 - o no dead space
 - o no avascular tissue (eschar and/or slough)
 - o no signs or symptoms of infection
 - o wound edges are open
- o **Early/partial granulation**
 - o $\geq 25\%$ of the wound bed is covered with granulation tissue
 - o $< 25\%$ of the wound bed is covered with avascular tissue (eschar and/or slough)
 - o no signs or symptoms of infection
 - o wound edges open
- o **3 - Not healing**
 - o wound with $\geq 25\%$ avascular tissue (eschar and/or slough) OR
 - o signs/symptoms of infection OR
 - o clean but non-granulating wound bed OR
 - o closed/hyperkeratotic wound edges OR
 - o persistent failure to improve despite appropriate comprehensive wound management

This guidance applies to surgical wounds closed by either primary intention (i.e. approximated incisions) or secondary intention (i.e. open surgical wounds).

(M1350) Does this patient have a Skin Lesion or Open Wound, excluding bowel ostomy, other than those described above that is receiving intervention by the home health agency?

WOUND OSTOMY CONTINENCE NURSES SOCIETY GUIDANCE ON OASIS-C INTEGUMENTARY ITEMS

GLOSSARY

Avascular	Lacking in blood supply; synonyms are dead, devitalized, necrotic, and nonviable. Specific types include slough and eschar.
Clean Wound	Wound free of devitalized tissue, purulent drainage, foreign material or debris
Closed Wound Edges	Edges of top layers of epidermis have rolled down to cover lower edge of epidermis, including basement membrane, so that epithelial cells cannot migrate from wound edges; Also described as epibole or hyperkeratotic. Presents clinically as sealed edge of mature epithelium; and wound edge may present clinically as hard/thickened; and/or discolored (e.g., yellowish, gray, or white).
Dead Space	A defect or cavity
Dehiscid / Dehiscence	Separation of surgical incision; loss of approximation of wound edges
Epidermis	Outermost layer of skin. New epidermis appears pink and dry and may look shiny. (Reference: Acute and Chronic Wounds, Nursing Management, Bryant Ruth, 2000, pg 21)
Epithelialization	Regeneration of epidermis across a wound surface
Eschar	Black or brown necrotic, devitalized tissue; tissue can be loose or firmly adherent, hard, soft, dry or wet.
Full Thickness	Tissue damage involving total loss of epidermis and dermis and extending into the subcutaneous tissue and possibly into the muscle or bone.
Granulation Tissue	The pink/red, moist tissue comprised of new blood vessels, connective tissue, fibroblasts, and inflammatory cells, which fills an open wound when it starts to heal; typically appears deep pink or red with an irregular, "berry-like" surface
Healing	A dynamic process involving synthesis of new tissue for repair of skin and soft tissue defects.
Hyperkeratosis	Hard, white/gray tissue surrounding a wound
Infection	The presence of bacteria or other microorganisms in sufficient quantity to damage tissue or impair healing. Wounds can be classified as infected when the wound tissue contains 100,000 or greater microorganisms per gram of tissue. Typical signs and symptoms of infection include purulent exudate, odor, erythema, induration, warmth, tenderness, edema, pain, fever, and elevated white cell count. However, clinical signs of infection may not be present, especially in the immuno-compromised patient or the patient with poor perfusion.
Necrotic Tissue	See avascular.
Newly epithelialized	The process of regeneration of the epidermis across a wound surface or regeneration of the epidermis across a wound surface
Non-epithelialized	The absence of regenerated epidermis across a wound surface.

WOUND OSTOMY CONTINENCE NURSES SOCIETY GUIDANCE ON OASIS-C INTEGUMENTARY ITEMS

Non-granulating	Absence of granulation tissue; wound surface appears smooth as opposed to granular. For example, in a wound that is clean but non-granulating, the wound surface appears smooth and red as opposed to berry-like.
Partial Thickness	Confined to the skin layers; skin damage that does not penetrate below the dermis and may be limited to the epidermal layers only.
Scab	A crust of dried blood and serum.
Sinus Tract	Course or path of tissue destruction occurring in any direction from the surface or edge of the wound; results in dead space with potential for abscess formation. Also sometimes called "tunneling". (Can be distinguished from undermining by fact that sinus tract involves a small portion of the wound edge whereas undermining involves a significant portion of the wound edge.)
Slough	Soft moist avascular (devitalized) tissue; may be white, yellow, tan, grey or green; may be loose or firmly adherent.
Tunneling	See sinus tract
Undermining	Area of tissue destruction extending under intact skin along the periphery of a wound; commonly seen in shear injuries. Can be distinguished from sinus tract by fact that undermining involves a significant portion of the wound edge, whereas sinus tract involves only a small portion of the wound edge.
Unhealed	The absence of the skin's original integrity.